



The Scientific Case Against Amalgam

The Case Against Amalgam	1
Amalgam releases significant quantities of mercury.	3
Mercury distributes to tissues around the body.	4
Maternal – fetal transfer of mercury.	9
Adverse physiological changes due to exposure to amalgam mercury.	10
Risk assessment.	10
Immune System:	12
Renal System:	12
Intestinal Flora:	13
Are we dentists harming ourselves?	14
The unique neurotoxicity of mercury, and the Alzheimer’s connection.	15
Neurite growth inhibition on video.	17
The anecdotes	18

Dental amalgam has been controversial ever since it was introduced, early in the nineteenth century, because of its mercury content. People of the Napoleonic era knew full well that mercury was poisonous, and the best that anyone has ever claimed about amalgam is that the mercury exposure may be too small to hurt anyone. Over time, though, a great body of evidence has accumulated showing that mercury is release from amalgam in significant quantities, that it spreads around the body, including from mother to fetus, and that the exposure causes physiological harm. A growing number of dentists, physicians, researchers, citizen activists, politicians, and regulators have come to the conclusion that the time has come to consign amalgam to the “dustbin of history.” This article will sketch out the main points of the scientific case against amalgam.

The history of amalgam is, of course, familiar. The alchemists of China and Europe were fascinated with mercury, the only metal that is liquid at room temperature, and which would evaporate with mild heat. They knew that liquid mercury could dissolve powders of other metals, such as tin, copper or silver. European methods for using a paste of silver shavings dissolved in mercury as dental restorations were introduced to America by the Crowcour brothers about 1830. Problems with excessive expansion in early amalgam were solved in time by adding the other, now customary metals – tin, zinc, and copper. The formula and technique for using amalgam has remained virtually unchanged for the past one hundred years.

The “first amalgam war” started almost immediately. The toxic effects of mercury, including dementia and loss of motor control, were common knowledge in the post–Napoleonic era, and many dentists objected to the obvious disadvantage of using such a dangerous material in people’s mouths. In 1845, the American Society of Dental Surgeons asked its members to sign a pledge never to use it. The economics were compelling, though,

as they remain today. At a time when the only other feasible restorative material was gold, amalgam looked to be the restorative material for the masses. Then, as today, patients did not show signs of acute poisoning as they left the dentist's office, so there did not appear to be a problem. As the use of amalgam grew, the American Society of Dental Surgeons fell apart, and in 1859, the pro-amalgam faction formed the American Dental Association, the same organization that leads the dental profession in the USA to this day, and remains steadfast in its defense of amalgam.

The "second amalgam war" was provoked in the 1920's by Professor Alfred E. Stock, a leading chemist at the Kaiser Wilhelm Institute in Germany. Adverse effects on his own health from mercury in the lab led him to question the supposed safety of mercury from dental amalgam. His research concluding that there were adverse health effects was published in leading scholarly journals of the day. It touched off a debate that raged through the 1930's without a clear resolution, only to fade away in the storm of World War II.

We are currently in the advanced stages of the third amalgam war. The argument was reopened in the late 1970's, as modern methods of detecting the presence of trace amounts of mercury were introduced, including mass spectrophotometry and the Jerome mercury vapor detector. We have accumulated a formidable body of evidence establishing the chain of toxic events: 1) amalgam releases significant amounts of mercury; 2) the mercury distributes to tissues around the body, and is the biggest source of mercury body burden; 3) the mercury from amalgam crosses the placenta and into breast milk, resulting in significant pre- and post-partum exposures for infants; and 4) adverse physiological changes occur from that exposure on the immune, renal, reproductive and central nervous systems, as well as the oral and intestinal flora.

A succinct but comprehensive review of this topic is: Lorscheider, FL, Vimy, MJ, Summers, AO. *Mercury exposure from "silver" tooth fillings: emerging evidence questions a traditional dental paradigm*. FASEB J. 9: 504-508 (1995). FASEB is the Federation of American Societies for Experimental Biology, and their journal is one of the world's highest rated scientific sources. They have published a number of important papers on this issue.

Organized dentistry could examine the emerging evidence and decide that it is time to change their minds about the traditional dental paradigm, although it appears more likely that they'll soldier on in denial. The four percent of dentists who think of biocompatibility first have long since abandoned amalgam, and the greater number who have joined the "esthetic dentistry" movement have, by and large, moved away from it as well. About 27% of US dentists are reported in 2001 to be practicing mercury free.¹ Will our profession accept a future of scientific progress and handle the legacy of amalgam in an enlightened way, or will we go down like DDT and asbestos, like big tobacco and nuclear waste?

This brief review will touch on the high points, the blockbusters in the case against amalgam. There is a vast literature on the subject, which can be further accessed in other articles available on this website, the [Bibliography of Mercury Topics](#), the [Swedish Government 2003 Report on Dental Amalgam](#), and [Status Report on Dentistry in the Environment](#), and on other websites provided in the Links section.

Amalgam releases significant quantities of mercury.

What kind of metal is amalgam? All the technical information we learn in dental school about an intermetallic matrix of gamma and mu phases only serves to obscure the fact that the mercury is not all reacted. Figure 1 is a photomicrograph of a polished metallurgical sample of amalgam which has been pressed on by a micro-probe.² Where the probe touched the surface, droplets of free liquid mercury are squeezed out into view. This process does not require heating the sample, as some have objected; it was repeated down to the temperature of liquid nitrogen.³

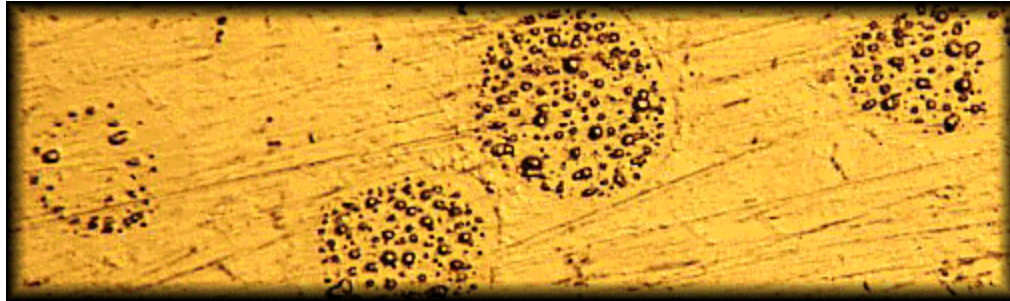


Figure 1 – Microscopic beads of liquid mercury expressed from the surface of amalgam metallurgical sample, following pressure from a microprobe. (from Masi, 1994)

The clearest, most gut wrenching way to comprehend that amalgam contains free mercury was discovered by IAOMT member Roger Eichmann, DDS. An extracted tooth containing an old amalgam filling is held in the light of a miner's blacklight, which is nothing but a fluorescent tube without phosphors – a pure mercury vapor discharge lamp. By the principles of atomic absorption spectrophotometry, the only cold vapor that could absorb the wavelength of mercury emission light and cast a shadow would be that of mercury itself. The filling in the photo in figure 2 has been dipped in 110⁰ F water, to simulate the type of mild heating one would expect from chewing, grinding the teeth, or drinking hot liquids. The smoke visibly emerging is the shadow of mercury vapor. A video version of this alarming demonstration entitled, "The Smoking Tooth," is available for download on the home page of this website. Click on the link, and watch the steady emission of mercury vapor, like smoke from a smoldering fire, from a filling that had been in someone's mouth for years. A pdf version with still photos is available for those without broadband internet.



Figure 2 – The smoking tooth.

This graphically dramatic process was hinted at by the fact that old amalgams contain significantly less mercury than new ones.^{4 5} It was quantified in the human mouth by Svare, et. al., Gay et. al., Vimy and Lorscheider, and others.^{6 7 8 9 10} By using a Jerome Mercury Vapor Detector and other methods, these groups were able to measure the mercury content of the air in the mouths of people with or without amalgams, before and after chewing. The baseline mouth air of people with amalgams contains more mercury than that of people without amalgams. After ten minutes of chewing gum, the mercury concentration in mouth

air does not change in subjects without amalgams, while for those with amalgam fillings it increases 8 – 10 fold, and remains elevated for at least 90 minutes.

Vimy and Lorscheider derived an average absorbed mercury dose of 10 µg per day from amalgam fillings from their measurements of mouth air.⁹ Other groups have reported varying estimates. On the low end, Mackert¹¹ and Berglund et. al.¹², by applying assumptions and inferences concerning how much mouth air is actually inhaled, arrived at average daily doses for subjects with twelve or more amalgam surfaces, of 1.83 and 1.7 µg, respectively (not zero). The question of inhaling mouth air should be moot, though, because elemental mercury vapor is lipophilic, and is absorbed easily through cell membranes and mucosal barriers. On the high end, Patterson et. al.¹³ reported absorbed doses of as much as 27 µg per day. Skare and Engqvist,¹⁴ by metabolic methods, arrived at a figure of 12 µg per day for a group of subjects with an average of 47 amalgam surfaces.

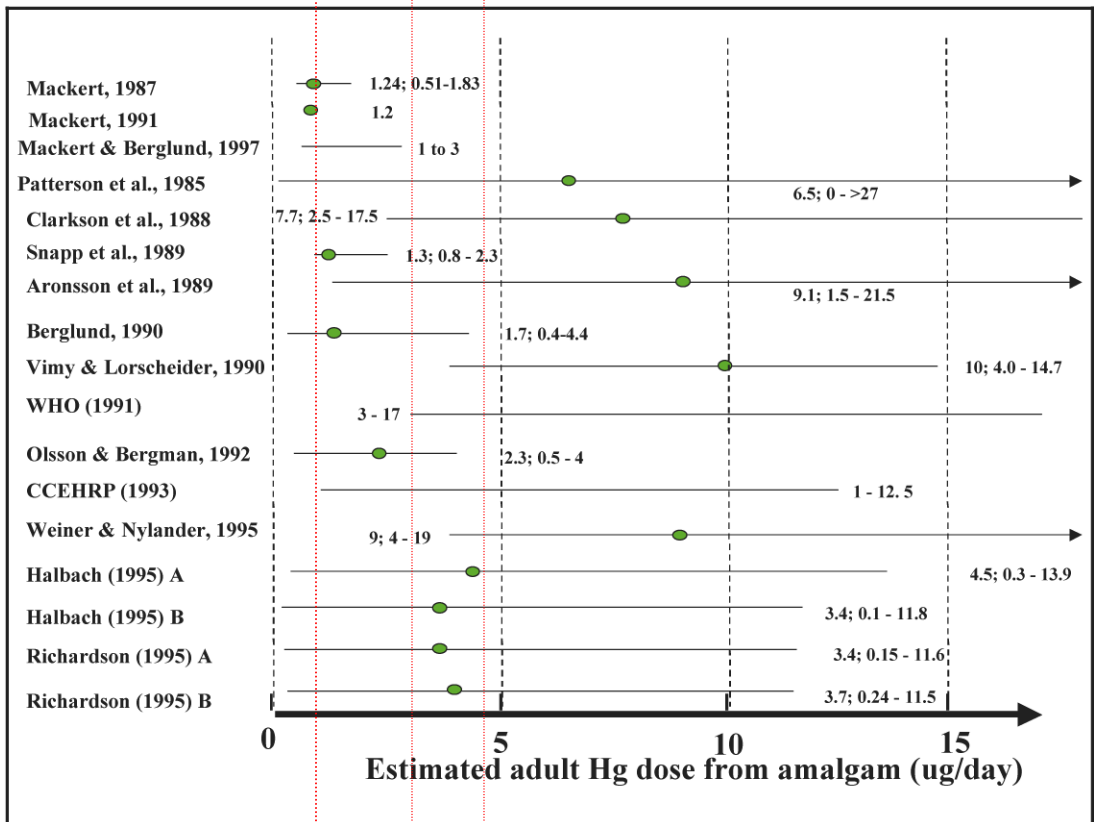
The current best accepted reference on absorbed dose of mercury from amalgam fillings comes from the World Health Organization proceedings of 1991¹⁵, which was the report of a meeting of toxicologists and environmental health specialists (few dentists and no industry lobbyists, the opposite of the 1997 WHO meeting!). The conclusion of that group was that the average person in the industrial world with an average number of amalgam fillings, and no occupational exposure to mercury would absorb between 3 – 17 µg per day, with an average of 10 µg, from the fillings; 2.3 µg from all dietary sources; and 0.3 µg from all other environmental sources.

Richardson¹⁶ presented a chart (figure 3) summarizing seventeen separate estimates of mercury exposure due to amalgam in adults. The range of the estimates intersects with limits recommended for non-occupational exposure by several agencies, including the Agency for Toxic Substances and Disease Registry of the US Public Health Service, Health Canada, and the US Environmental Protection Agency, as shown by the vertical red lines.

Mercury distributes to tissues around the body.

One of KO Frykholm's experiments in his landmark 1957 study¹⁷ of mercury in amalgam involved giving eight volunteers four new fillings each, labeled with radioactive ²⁰³Hg. He was able to detect excretion of the radioactive mercury in urine for seven days, and in feces for thirteen days. From this he concluded that the release of mercury from the fillings, while not zero, was self limiting, and should therefore be no problem for the exposed people. The "no problem" conclusion was not supported by toxicology, and there was no discussion of the possible retention in the body of some of that radioactive mercury. Nevertheless, this study has been relied upon by supporters of amalgam ever since, as proof that there is "no problem."

In the late 1980's, Murray Vimy, Fritz Lorscheider and their group undertook to use radioactive mercury to examine the question of tissue retention of mercury from amalgams fillings, in a series of experiments supported by the IAOMT. Vimy, a founding member of the IAOMT, is a general dentist in Calgary, Alberta, and Lorscheider, now retired, was a professor of physiology at the University of Calgary Medical School. They enlisted the help



- US EPA reference air concentration for non-occupational exposure, calculated dose 4.8 µg/d (www.epa.gov/iris/subst/0370.htm#refinhal)
- ATSD- MRL calculated dose 3.2 µg/d, US Dept of Health and Human Services. (<http://atsdr1.atsdr.cdc.gov/toxprofiles/tp46-a.pdf>)
- Health Canada reference dose, 0.98 µg/d, Richardson (1996)⁵³

Figure 3 – Summary of seventeen literature citations estimating average mercury exposure in adults from amalgam fillings. The intersecting red lines show current allowable limits for non-occupational mercury to inorganic mercury from three different government agencies. The green dot in each horizontal bar represents the mean exposure found in that particular agency's study. Adapted with publisher's permission from Richardson, GM; Human and Ecological Risk Assessment, 9: 1519-1531 (2003)

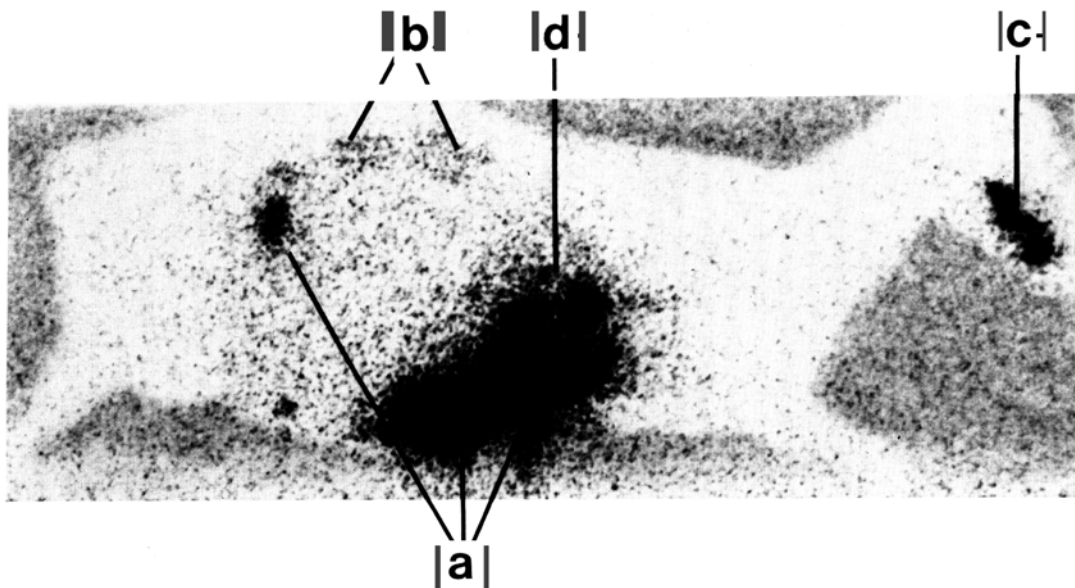


Figure 4 – Full body scan of a sheep 29 days after placement of 12 occlusal amalgams labeled with ^{203}Hg . The fillings were removed prior to the scan. (a) digestive tract. (b) kidneys. (c) gums and alveolar bone. (d) liver, partially obscured by the digestive tract. (From Hahn, et. al., 1989)

of the medical school's extensive animal program, and placed twelve occlusal fillings tagged with radioactive ^{203}Hg in the mouth of a sheep. The fillings were over-carved, not left high in the occlusion, as some have alleged, and the operators were careful to rinse all amalgam particles from the animal's mouth after placement. After twenty nine days, the sheep was killed, and the coronal portions of the teeth containing the radioactive fillings were removed. The sheep was placed in a full body gamma ray scanner, and the picture in figure 4 was the result.¹⁸

The graphic results are dramatic. Figure 4 is a full body gamma scan of the experimental sheep, showing translocation of radioactive mercury from the amalgam fillings into several organs. The teeth had been extracted prior to scanning, and the high concentration of radioactivity in the mouth region demonstrates movement of mercury into the jawbone from the fillings. The table below shows tissue concentrations of mercury that disseminated around the sheep's body. Control numbers would have been zero – all this mercury derived from the amalgam fillings, because the numbers were calculated from counts of radioactivity. In this experiment, the organ that accumulated the greatest amount of mercury was the kidneys, 7438 nanograms per gram of tissue (ng/g). The urine concentration was only 4.7 ng/g, demonstrating the inadequacy of plain urine samples as an indicator of mercury storage in internal organs. The order of magnitude of mercury accumulation in liver and kidney was confirmed by further studies using radioactive fillings in sheep.¹⁹

Tissue	ng Hg/g
Whole blood	9.0
Urine	4.7
Skeletal muscle (gluteus)	10.1
Fat (mesentery)	0.9
Cortical maxillary bone	3.6
Tooth alveolar bone	318.2
Gum mucosa	323.7
Mouth papilla	19.7
Tongue	13.0
Parotid gland	7.8
Ethmoturbinal (nasal) bone	10.7
Stomach	929.0
Small intestine	28.0
Large intestine	63.1
Colon	43.1
Bile	19.3
Feces	4489.3
Heart muscle (ventricle)	13.1
Lung	30.8
Tracheal lining	121.8
Kidney	7438.0
Liver	772.1
Spleen	48.3
Frontal cortex	18.9
Occipital cortex	3.5
Thalamus	14.9
Cerebrospinal fluid	2.3
Pituitary gland	44.4
Thyroid	44.2
Adrenal	37.8
Pancreas	45.7
Ovary	26.7

The dental establishment reacted with characteristic speed and determination. The “sheep experiment” was criticized for using an experimental animal that ate and chewed very differently from humans, and for not controlling for environmental factors, such as mercury in the diet. Of course, the experiment was not designed to look for mercury, but rather for radioactivity. There is no radioactive ^{203}Hg in nature, so any of it found could only have come from the fillings. The authors responded to the first criticism by saying that the sheep represents the “exacerbated case.” If spread of mercury from amalgam could not be found in such a chewing machine as a sheep, the case would be closed, and the controversy over.

The same experiment was repeated using a monkey, which would eat much the same food and chew in much the same way as humans. The results were virtually identical to those found with the sheep.²⁰ Within twenty eight days, the radioactive mercury had spread

around the monkey's body, yielding tissue concentrations that were highly similar to the sheep's. The monkey experiment was confirmed by Danscher, et. al.²¹ in Denmark. Figure 5 is the full body scan of the experimental monkey. Again, the teeth were sectioned and the coronal fillings removed prior to the scan.

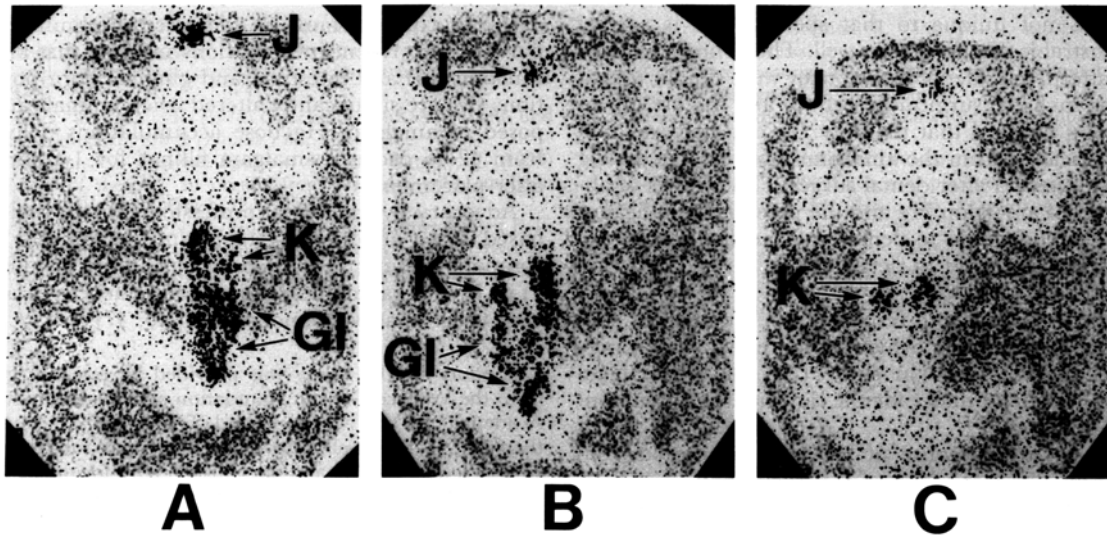


Figure 5 – Full body scan of a monkey 28 days after the placement of 16 occlusal fillings, labeled with ²⁰³Hg, showing radioactivity in the jaws, kidneys and GI tract. (A) ventral view. (B) dorsal view. (C) dorsal view with the GI tract removed, clearly showing radioactive mercury accumulation in the kidneys. (From Hahn, et. al., 1990)

There is a large body of scientific literature that shows that amalgam-derived mercury spreads around the body, and that amalgam typically provides the greatest portion of the mercury to be found in the human body. Several autopsy studies showed a correlation between the mercury concentration in various tissues and organs of the human cadavers and the number of fillings or surfaces of amalgam present.^{22 23 24 25 26} Blood levels of mercury correspond to amalgam exposure.^{27 28 29} Subjects with amalgam excrete higher amounts of mercury in the feces.^{30 31} Mercury in urine, blood, and feces declines after amalgam removal.^{32 33 34}

Aposhian et. al.,³⁵ investigating the use of DMPS (2,3 dimercapto propane 1 sulfonic acid) as a chelating agent to remove toxic metals from the body, gave the drug to a group of subjects with amalgam fillings, and a control group of subjects who had never had amalgams. Urinary excretion of mercury in the non-amalgam group increased from 0.27 µg to 5.1 µg over a nine hour period, while among the amalgam subjects it went from 0.7 µg to 17.2 µg. They concluded that two thirds of the mercury excreted in the urine must derive from the amalgam fillings. They also reported a highly significant correlation between amalgam score and urinary excretion of mercury two hours after DMPS administration. Other labs report similar results.^{36 37}

Maternal – fetal transfer of mercury.

Babies, with their still-developing nervous systems, are known to be more sensitive to the effects of mercury exposure than adults. Pediatric authorities say: “The developing fetus and young children are thought to be disproportionately affected by mercury exposure, because many aspects of development, particularly brain maturation, can be disturbed by the presence of mercury. Minimizing mercury exposure is, therefore, essential to optimal child health.” And “Mercury in all of its forms is toxic to the fetus and children, and efforts should be made to reduce exposure to the extent possible to pregnant women and children as well as the general population.”³⁸

This was made tragically clear in the case of the Minamata Bay methyl mercury poisoning, in Japan in the 1960’s, where children were born with profound developmental disturbances, while the adults suffered much less. There is a substantial experimental literature on the neuro-teratological effects of mercury, where both humans and animals exposed to low doses of mercury *in utero* and soon after birth show measurable deficits in intelligence, coordination, and other measures of neurological development^{39 40 41 42 43 44 45} (and hundreds more). And now there is an added controversy about vaccines preserved with thimerosal, a form of ethyl mercury, possibly causing neurological damage in infants, including autism.⁴⁶ Does amalgam use in dentistry provide the unborn with a prenatal body burden of mercury?

Two more experiments by Vimy, Lorscheider and associates at the University of Calgary Medical School, supported by the IAOMT, provide some insight into the issue of amalgam-derived mercury exposure to the fetus and infant. In the first,⁴⁷ five pregnant ewes, at about 112 days of gestation, were fit with indwelling catheters that allowed the researchers to collect serial samples of maternal and fetal blood, amniotic fluid, plus maternal feces and urine. Each sheep received twelve occlusal amalgam fillings labeled with radioactive ²⁰³Hg, as did the sheep in the original study. The various body fluid samples were collected for sixteen days, after which the sheep were sacrificed at intervals and tissue samples were analyzed for radioactive mercury. They found that the amalgam-derived mercury appeared in maternal and fetal fluids within two days of amalgam placement. Radioactive mercury was found in all post-mortem tissues studied. Tissue concentrations achieved steady state levels after about a month, levels that were maintained throughout the 140 day course of the experiment. The fact that tissue concentrations did not decline with time, as they would have with an acute, one time dose, implies that there was an ongoing exposure from the radioactive amalgam fillings. As before, the mothers concentrated the most mercury in the kidneys and liver, while the fetuses concentrated it in the liver and pituitary gland. Mercury concentration in the fetal blood was actually higher than in the maternal blood.

In the second study,⁴⁸ pregnant ewes received radioactive amalgams as before, and then nursed either their own lambs or foster lambs that had not been exposed to radioactive mercury in the womb. In the womb, the fetal lambs accumulated more mercury in the liver, while after birth the kidneys became the primary site of accumulation. Measurable quantities of radioactive mercury appeared in the tissues of both amalgam-bred lambs and those only nursed by amalgam-bearing ewes.

These studies are consistent with the work of other groups. For example, previous animal studies have shown that when the mother is exposed to Hg^0 , the form of mercury that is emitted from amalgam, fetal tissues take up more mercury than when the mother is exposed to Hg^{2+} .⁴⁹ Drasch, et. al.⁵⁰ studied autopsy samples from human stillbirths and early post natal deaths. They found that the mercury concentration in the infants' kidneys, liver and cerebral cortex correlated significantly with the mother's amalgam scores. Two labs also found that mercury concentration in human breast milk correlated significantly with the mothers' amalgam scores.^{51 52}

Adverse physiological changes due to exposure to amalgam mercury.

So – all this exposure information is one thing, but as we have heard for years, “the dose makes the poison,” and “no one has found dental amalgam to have caused any human disease, except for very rare allergic reactions.”

Well, it's not exactly true. It is true that in the huge body of information on mercury toxicity the greatest number of papers concern acute doses. Relatively few experiments have been done on chronic trace level exposure to elemental mercury vapor, and fewer still made use of amalgam as the mercury source. But there are some very provocative indications in the literature. A picture emerges, not of overt disease, but of many subtle (and some not so subtle) biochemical and physiological events that together constitute the pathophysiology of chronic low level mercury poisoning from exposure to dental amalgam. Certainly there are many suggestions that chronic exposure to mercury can contribute to big-name diseases. [see www.bioprobe.com for a bibliography, or read *The Toxic Time Bomb*, available on that site] But that concept is not necessary to warrant caution in using mercury. After all, who would wait for proof that lead or arsenic caused a “disease” before avoiding these known poisons?

Risk assessment.

In the early 1990's, Health Canada was sued by a group of consumer activists over a law requiring an evaluation of safety and effectiveness for all medical devices. They eventually forced the agency to apply that standard to dental amalgam. A staff specialist in medical risk assessment, G. Mark Richardson, was assigned the task of evaluating the available literature on mercury and amalgam, and to make recommendations concerning the health impacts of amalgam use in Canada.^{53 54}

Richardson made detailed recalculations of mercury exposure from amalgams based upon the reported literature, and detailed recalculations of the level of mercury vapor exposure that would lead to “subclinical impairment of neurological and cognitive functions,” based on the industrial hygiene literature. His general assessment was, in essence, that somewhere within the known range of mercury exposure from amalgam, there begins the known range of mercury exposure that produces neurological consequences. Based on his examination of the neurological data, he proposed a tolerable daily intake (TDI) of $.014 \mu\text{g Hg}^0/\text{kg-day}$, which was exceeded in all age groups by the average daily exposure

from amalgam in Canada. In order not to exceed the proposed TDI, the maximum number of amalgam fillings allowed would have to be:

Ages 3 – 11	0 – 1
12 – 19	1 – 3
20 – 59	2 – 4
60 +	2 - 4

If the US EPA non-occupational “reference concentration” of $0.3 \mu\text{g Hg}/\text{m}^3$ in air were to be used, 9 – 11 amalgam fillings would be acceptable in an adult. On the other hand, the US Agency for Toxic Substances and Disease Registry (ATSDR) published a minimal risk level (MRL) for non-occupational exposure of $.014 \mu\text{g Hg}^0/\text{m}^3$ in air. If this standard were used, even one amalgam would expose the individual to more mercury than would be allowed by Richardson’s proposed TDI. (see fig 3, above)

Richardson concluded that, “no clear threshold for subclinical neurological and cognitive function impairment is evident from published studies of the CNS effects of Hg vapor.” In other words, no known safe level. Further, “the continued unconditional and unlimited use of amalgam as a dental restorative material, the placing of up to 25 amalgam fillings in one individual, is not supported by the available risk information.”

The Canadian Dental Association called this report “unscientific,” but later retracted that statement. Health Canada did not support a total ban on amalgam use, but, in 1996, did issue some restrictive recommendations:⁵⁵

- Avoid using mercury to restore children's teeth.
- Avoid placing or removing amalgam in the teeth of pregnant women.
- Avoid using dental amalgams in patients suffering from kidney ailments.
- Use methods and equipment to reduce the risks of exposure to mercury vapor to protect their patients and their staff. [This is the subject of a later chapter in this on-line book.]
- Avoid using amalgams in patients who risk suffering from allergic hypersensitivity (5 to 15% of the population).
- On the advice of a physician, remove amalgams from a patient who has become sensitive.
- Avoid placing amalgam in contact with other metal appliances in the mouth (orthodontic appliances, etc).
- Fully inform patients of the risks and benefits involved.
- Recognize the patient's right to refuse treatment using a “specific material.”

Immune System:

The “allergic hypersensitivity” to mercury issue is interesting. It is not very, very rare, as certain dental authorities would have us believe. The North American Contact Dermatitis Group, in 1972, determined that 5 - 8% of the US population demonstrates allergy to mercury by skin patch testing.⁵⁶ By using antibody – antigen flocculation tests on blood serum, the number is over 90%.⁵⁷ Djerassi and Berova⁵⁸ patch tested 180 subjects with amalgam fillings, and found that 16.1% of those without allergic disease, and 22.5% of those with allergic disease, tested positive for mercury allergy. Of sixty subjects without amalgam fillings, none tested positive for mercury allergy. In a study of 29 patients with oral lichen planus, 62% were positive for mercury allergy.⁵⁹ And at Baylor College of Dentistry, of 171 dental students patch tested, 32% were positive for mercury allergy. The percentage of positive tests correlated with the students’ own amalgam scores, and with the length of time they had been in dental school.⁶⁰

Mercury exposure is known to induce autoimmune reactions in susceptible animals,⁶¹⁶²⁶³ and one investigation shows the same for amalgam. Hultman et. al.⁶⁴ implanted gelatin coated particles of either finished amalgam or unmixed silver alloy in the peritoneal cavity of mice known to be genetically susceptible to mercury–induced autoimmune reactions. Over the course of the experiment, both groups displayed their characteristic reactions of hyperimmuno-globulinemia, serum autoantibodies targeting nucleolar proteins, and systemic immune complex deposits. The authors ascribed the reactions in the alloy–only group to the silver component.

Think of the outbred human population, with its plethora of autoimmune diseases. We dentists have developed no method of screening our patients for contact dermatitis or for their susceptibility to metal–sensitive autoimmune responses. Knowing these mechanisms exist, how many such problems are we creating by using mercury – or nickel, for that matter?

Renal System:

Mercury, we now know, concentrates in the kidneys, and experimental evidence shows that it can inhibit kidney function.⁶⁵ But can mercury deriving from amalgam fillings have a direct effect upon kidney function? Once again in Calgary, six sheep received amalgam fillings, although they were not radioactive this time. Two control sheep received glass ionomer fillings. Renal clearance tests were performed before the fillings were placed and again at thirty and sixty days following. All six of the experimental sheep had a statistically significant decrease in their inulin clearance at both thirty and sixty days relative to the controls, with an average decline of 54%, $p < .01$. (see figure 6) They also had a significant increase in urinary sodium, and a decrease in urinary albumin as compared to the controls. The kidney tissue showed no structural change upon microscopic examination.⁶⁶ Molin, et. al.⁶⁷ reported that urinary albumin increased in humans one year after removal of amalgams. Mercury is known to concentrate in the proximal tubules, which are the primary site of sodium reuptake, so it makes sense that urinary sodium excretion increased if the mercury is inhibiting the function of those cells.

Although these effects could be described as “subclinical,” in that overt disease was not induced, it demonstrates how much stress is placed upon the kidneys by the presence of amalgam, and suggests how patients with kidney malfunction may be endangered by amalgam fillings.

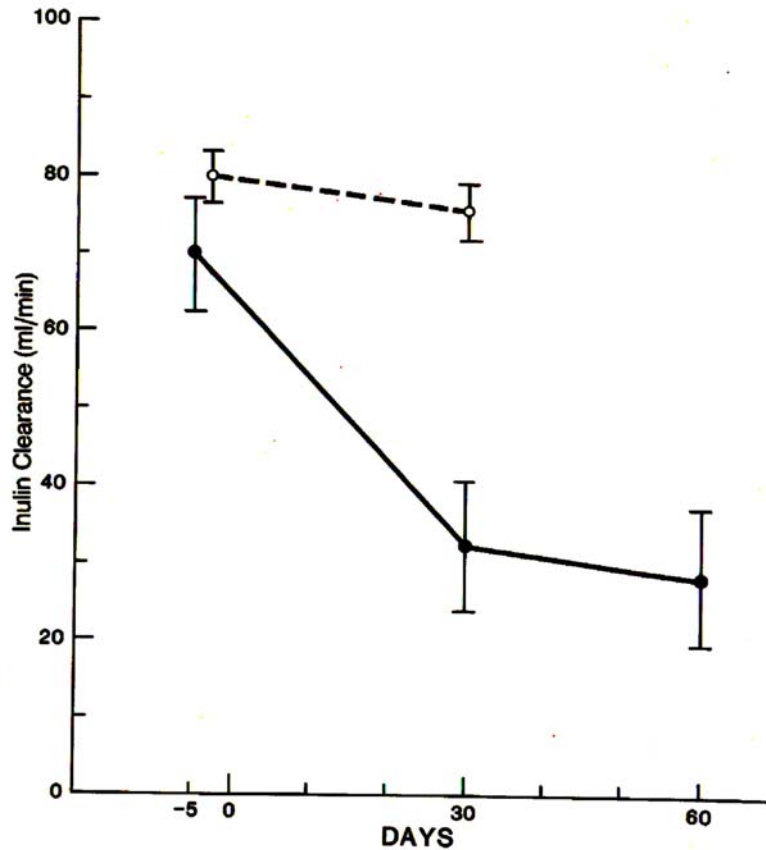


Figure 6 – Plasma inulin clearance (+/- SEM) of six sheep with twelve occlusal amalgam fillings (solid line) and two controls with glass ionomer fillings (dashed line). (from Boyd, et. al., 1991)

Intestinal Flora:

Anne Summers and her group in the Department of Microbiology, University of Georgia, were investigating resistance to antibiotics among intestinal bacteria when they discovered an unexpectedly high percentage of resistance in the flora of individuals who had had no recent exposure to antibiotics. They found that the genes for antibiotic resistance in these bugs were linked, on plasmids, to a gene for resistance to mercury toxicity. Therefore, subjects with a high percentage of mercury resistant bacteria in their intestines were significantly more likely to have bacteria with multiple antibiotic resistance as well. It was ecological pressure for mercury resistance that seemed to be maintaining the high prevalence of resistance in these gut flora samples. But where was the mercury coming from?⁶⁸

To test the hypothesis that dental amalgam could provide enough mercury exposure to drive this ecological selection, monkeys were given amalgam fillings. Their intestinal

flora showed a marked increase in the proportion of mercury resistant bacteria, and the increase was maintained until the amalgams were removed. Most of the mercury resistant microbes also possessed resistance to one or more antibiotics.⁶⁹

The implication of this finding for human medicine is unproven, but disturbing to contemplate. At least it shows again that amalgam, while perhaps not causing overt disease, has a detectable effect upon the homeostasis of the body that is not benign.

Are we dentists harming ourselves?

One of the mantras chanted in support of amalgam has been that dentists' health status is not different from that of the general population, despite the fact that we are exposed in our work to mercury. Perhaps, one might say, that's due to the mercury hygiene rules promulgated by the profession – don't touch mixed amalgam with the hands while you pack it into patients' teeth, store scrap amalgam in tightly closed containers under various liquids to prevent vapors from escaping in the office, dispose of it with licensed hazardous waste handlers, etc. Even so, there is some evidence that mercury-exposed dentists and staff do suffer various effects.

In one study, dentists with high baseline urinary mercury levels showed neuropsychological and motor control deficits.⁷⁰ In another, dentists and staff with high mercury levels, proven by DMPS challenge, had altered porphyrin (hemoglobin) metabolism, as well as neurobehavioral changes, including impairment of attention, motor and perceptual skills, and increased irritability.^{71 72}

The urinary mercury levels of 4272 dentists were measured at random at dental conventions by Naleway,⁷³ et. al., between 1975 to 1983. They found that dentists *on average* did not have urinary mercury concentrations outside “acceptable limits” and came to the conclusion that there was no problem with their occupational exposure due to amalgam. However, the urinary concentrations correlated significantly ($p < .001$) with the number of amalgams each dentist placed per week, and the range was tremendous. The general population has a range of 0 – 5 µg Hg per liter of urine, while 10.9% of the dentists in this study had over 30 µg per liter, including 1.3% with over 100 µg per liter! If the proportionality of mercury in urine to total body burden, as shown by the sheep and the monkey studies, holds true for humans, the dentists who use the most amalgam are storing prodigious quantities of mercury in their bodies.

In a survey of 7,000 female dental assistants, a subgroup of 418 women who placed over 30 amalgams per week, and had poor mercury hygiene habits, had a fertility rate of 63% that of control women not exposed to mercury.⁷⁴ Many other studies point to a negative effect of mercury vapor exposure on reproductive outcomes.^{75 76 77 78}

Depression and mood alteration is a known feature of chronic mercury toxicity.⁷⁹ Dare we speculate that occupational mercury exposure plays a part in the suicide rate of dentists, which is higher than the population average?

The unique neurotoxicity of mercury, and the Alzheimer's connection.

The scene shifts to the Sanders-Brown Center on Aging at the University of Kentucky, which has a very active program for the study of Alzheimer's disease (AD). Autopsy specimens of the AD brain show certain diagnostic lesions – deposition of amyloid protein plaques, and neurofibrillar tangles, remnants of degenerated axons. There are characteristic biochemical lesions as well, including phosphorylation of tau protein, depletion of intracellular glutathione and creatine kinase, excess production of glutamine synthetase, and disruption of tubulin formation. Most of the research that we hear about in the press in the last few years has concentrated on the amyloid plaques, although amyloid deposition is found in many diseases, in other organs. The neurofibrillar tangle is more unique to AD, but there hasn't been an experimental system with which to study it until recently.

Following one track, Markesbury, Ehmann, Vance, and associates published a series of papers in which they described a variety of trace mineral changes in AD brain as compared to controls from patients with other psychiatric diseases or normal brains. They consistently found elevated concentrations of mercury, in various regions and subcellular fractions in the AD brain samples.^{80 81 82 83} Other labs found elevated mercury in the blood and cerebrospinal fluid of AD patients.^{84 85}

An examination of the same topic that was published with great fanfare in the Journal of the American Dental Association, along with press releases heralding the exoneration of amalgam, showed no correlation between amalgam history and AD, nor differences in mercury concentration between AD brains and controls.⁸⁶ This is the only paper in existence that presents such a position, contradicting those mentioned above, and the other human autopsy studies quoted earlier.

Meanwhile, Boyd Haley, a protein biochemist and chairman of the chemistry department at the University of Kentucky, was working on the tubulin synthesis defect in AD with his associate Kurt Pendergrass and their group. Haley had developed a chemical probe for the active site of an enzyme that he called "photo-affinity labeling," which has since become a standard tool in biochemical research. The technique involves a photoreactive chemical bridge between the substrate molecule and a radioactive $^{32}\text{PO}_4$ group. In the test tube, the target enzyme is allowed to react with the prepared substrate, and then exposed to light. The light causes the photoreactive bridge to disintegrate, allowing the highly active $^{32}\text{PO}_4$ to staple itself to the protein. If the enzyme's active site is not available, blocked by a mercury atom or other inhibitor, the photo-labeling will not take place. To summarize – if the active site is open, the protein becomes radioactive. If the active site is blocked, the protein is there, but does not become radioactive.

Haley, Pendergrass and associates used this technique to work out the biochemical mechanism behind the tubulin synthesis defect in AD, and linked it firmly to mercury. Tubulin is a structural protein in all cells, forming the girders and beams of the cytoskeleton. It is a large polymer made up of dimeric units, each having an α and β subunit. In order for the two to join, the β -subunit must bind a GTP molecule. The researchers found that the β -tubulin from AD brain could not bind photolabelled $^{32}\text{PO}_4$ -GTP. The protein was there, but the active site was blocked!⁸⁷

Taking a hint from their colleagues at the Sanders Center, they investigated the possibility that toxic minerals could be blocking the GTP binding site on β -tubulin. To make a long story short, it turns out that the binding site on β -tubulin is uniquely blocked by mercury, at extremely low concentrations in the 10^{-7} M range. Cadmium has a smaller effect, by orders of magnitude, and aluminum and lead have no effect at all. Excess zinc had a slight effect, but greatly increased the inhibitory action of the low concentrations of mercury.^{88 89 90}

The mercury story is making its way in the laboratory, if not yet in the press. Recently, Olivieri, et. al.⁹¹ reported that adding a very low concentration of mercury, 36×10^{-9} M, to neuroblastoma cells in tissue culture caused them to exhibit all the biochemical lesions of AD – inhibited tubulin synthesis, drop in intracellular glutathione, excretion of phosphorylated tau protein, and finally, excretion of β -amyloid. If most contemporary researchers think that amyloid is the cause of AD, here we have vanishingly small quantities of mercury causing amyloid in turn. The authors of this study suggest that mercury is the ultimate cause of these events.

Closer to our world, research shows that this test tube phenomenon can be induced in living animals. Mercury chloride has been shown to get into rat brains and inhibit the binding of GTP to β -tubulin,⁹² and the same for elemental mercury vapor. Rats breathing $300 \mu\text{g Hg}^0$ per cubic meter of air, a concentration that has been found in the mouths of people with lots of amalgam, for just four hours a day for fourteen days, had 75% inhibition of the photolabeling of β -tubulin with $^{32}\text{PO}_4\text{-GTP}$.^{93 94} Did the rats become demented? That question was not asked. Perhaps this was a subclinical effect, one that did not cause overt disease. But is it not an effect we would wish to avoid?

The mercury story correlates with an epidemiological feature of AD. The age of onset of AD in the population is associated with the genetic variation of apolipoprotein-E, a “housekeeping” protein in the brain and cerebrospinal fluid. Its usual function appears to be transport of cholesterol. However, it comes in three genotypes, apo-E2, apo-E3, and apo-E4. Those individuals with apo-E2/2 almost never get AD, while those with apo-E4/4 tend to have early onset of the disease. Apo-E3 is intermediate. What’s the difference among the genotypes? At amino acid position 112 and 158, apo-E2 has two of the sulfhydryl containing cysteine molecules. Apo-E3 has arginine at position 158, and apo-E4 has arginine at both places. In other words, apo-E2 has the most capacity to bind and remove divalent toxic metal atoms such as mercury as it moves from the brain into the cerebrospinal fluid, and out into the blood. Apo-E3 has less, and apo-E4 has none, at least by this mechanism.⁹⁵

Dentists, we can be certain, have never screened patients for their apo-E genotype before exposing them to mercury in fillings.

Neurite growth inhibition on video.

What is it about Calgary? One of the few labs in the world that has the capacity to maintain growing neurons in tissue culture is at the University of Calgary Medical School. Very recently, a group there, supported in part by the IAOMT, published a paper and an accompanying video that shows how very low concentrations of mercury chloride, at 10^{-7} M again, causes the tubulin in the growth cones of young neurites to fall apart.⁹⁶ The subject cells were the large Pedal A neurons from the central ring ganglia of the snail *Lymnaea stagnalis*. The amino acid sequence of tubulin is at least 97% the same throughout the animal kingdom, so there is no difficulty comparing snail tubulin with human. Figure 7 is a series of still photographs from this experiment, which shows first the intact growth cone. Then the mercury solution is applied with a micropipette. Finally, seventeen minutes later, the growth cone has degenerated, leaving behind a tangle of neurofibrillar protein, reminiscent of those seen in AD brains. In another trial, growth-phase neurons in a culture medium containing 10^{-7} M mercury chloride failed to initiate growth cones. Other elements, aluminum, lead, cadmium and manganese were tried, but they produced neither effect.

The authors state: “Hg ions markedly disrupted membrane structure and linear growth rates of imaged neurites in 77% of all nerve growth cones. When growth cones were stained with antibodies specific for both tubulin and actin, it was the tubulin/microtubule structure that disintegrated following Hg exposure.”

The complete paper is available on-line at this URL:
<http://ipsapp002.lwwonline.com/J=1860&I=88&A=21&U=1&T=0>

If you have a fast internet connection, you can view the video of this experiment at:
<http://movies.commonscalgary.ca/mercury/>.

It is a miracle of nature and evolution that we are so elaborately protected from diseases and toxins. We have, in the case of mercury and the other divalent metal toxins, essential metabolic systems such as reduced glutathione, metallothionines, and apolipoprotein-E which double as protective elements. But, as we have seen in the case of apo-E, there are genetic variations and polymorphisms that inevitably leave some individuals more vulnerable to assault. We dentists may never have a perfect understanding of biocompatibility. We may always be forced into biological compromises with our need to implant synthetic materials in our patients' mouths. But let us at least minimize that risk where the science is firm. Amalgam has got to go. And if the mercury–Alzheimer's disease connection holds up, our profession is going to need some heavy rain gear.

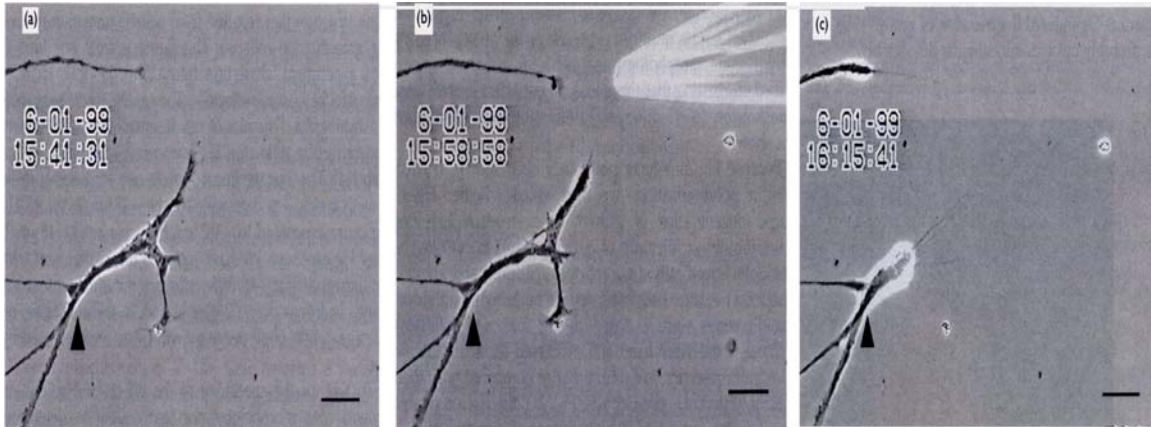


Figure 7 – Retrograde degeneration of neurite growth cone in the presence of 10^{-7} molar mercury chloride. Note the triangle reference mark. (From Leong, et. al. 2000)

The anecdotes

The world and the world wide web are full of anecdotes from people who claim their health improved once their amalgam fillings were replaced with other materials. These are real people with real life experiences, though their stories do not constitute scientific cause and effect evidence. Nevertheless, the scientific method requires that we observe natural phenomena, so as to gather ideas which we can try to develop into testable hypotheses. Where there's smoke there just might be fire.

The following is a summary of the subjective reports of 1569 patients who participated in six different surveys of health effects of replacing amalgam fillings.⁹⁷

Symptom Reported	Percentage of patients claiming substantial relief
Allergy	89 %
Anxiety	93
Bad temper	89
Bloating	88
Blood pressure problems	54
Chest pains	87
Depression	91
Dizziness	88
Fatigue	86
Gastrointestinal problems	83
Gum problems	94
Headaches	87
Migraine	87
Insomnia	78
Irregular heartbeat	87
Irritability	90
Lack of concentration	80
Lack of energy	97

Memory loss	73
Metallic taste	95
Multiple sclerosis	76
Muscle tremor	83
Nervousness	83
Numbness	82
Skin disturbances	81
Sore throat	86
Tachycardia	70
Thyroid problems	79
Oral ulcers	86
Urinary tract problems	76
Vision problems	63

© IAOMT, 2002 2005, by Stephen M. Koral, DMD

References

- ¹ Clinical Research Associates Newsletter, December 2001
- ² Masi, JV. Corrosion of Restorative Materials: The Problem and the Promise. Symposium: Status Quo and Perspectives of Amalgam and Other Dental Materials, April 29-May 1, (1994).
- ³ Masi, JV. Personal communication
- ⁴ Radics, L; Schwander, H; Gasser, F. [The crystalline components of silver amalgam studied using the electronic x-ray microprobe] ZWR 79:1031-1036 (1970) [German].
- ⁵ Gasser, F. [New studies on amalgam] Quintessenz 27: 47-53 (1976) [German].
- ⁶ Gay et al. Chewing Releases Mercury from Fillings. Lancet, 985, 5 May 1979.
- ⁷ Patterson, JE; et al. Mercury In Human Breath From Dental Amalgams. Bull Environ Contam Toxicol., 34:459-68, (1985).
- ⁸ Vimy, MJ; Lorscheider, FL. Dental amalgam mercury daily dose estimated from intro-oral vapor measurements: A predictor of mercury accumulation in human tissues. J Trace Elem Exper Med, 3:111-23, (1990).
- ⁹ Vimy, MJ; Lorscheider, FL. Serial measurements of intra-oral air mercury: estimation of daily dose from dental amalgam. J Dent Res, 64:1072-1075, (1985).
- ¹⁰ Svare, CW; Peterson, LC; Reinhardt, JW; Boyer, DB; Frank, CW; Gay, DD; and Cox, RD. The effects of dental amalgams on mercury levels in expired air. J Dent Res, 60" 1668-1671, (1981).
- ¹¹ Mackert, JR. Factors affecting estimation of dental amalgam mercury exposure from measurements of mercury vapor levels in intraoral and expired air. J Dent Res 66:1775-1780 (1987).
- ¹² Berglund, A. Estimation by a 24 hour study of the daily dose of intra-oral mercury vapor inhaled after release from dental amalgam. J Dent Res 69: 1646-1651 (1990).
- ¹² Patterson, op. cit.
- ¹⁴ Skare, I; Enkvist, A. Human exposure to mercury and silver released from dental amalgam restorations. Arch Environ Health. 49: 384-394 (1994).
- ¹⁵ World Health Organization): Environmental Health Criteria, Vol. 118: Inorganic Mercury. Pg. 61. WHO, Geneva, Switzerland, 1991.
- ¹⁶ Richardson, GM. Inhalation of Mercury-contaminated Particulate Matter by Dentists: an Overlooked Occupational Risk. Human and Ecological Risk Assessment 9: 1519-1531, 2003.
- ¹⁷ Frykholm, KO. On mercury from dental amalgam: its toxic and allergic effects and some comments on occupational hygiene. Acta Odontol Scand. 15 (supplement22): 7-108 (1957).
- ¹⁸ Hahn, LJ; Kloiber, R; Leininger, RW; Vimy, MJ; Lorscheider, FL. Dental "silver " tooth fillings: a source of mercury exposure revealed by whole body scan and tissue analysis. FASEB J, 3:2641-6, 1989.

-
- ¹⁹ Vimy, MJ; et al. Mercury from Maternal "Silver Fillings in Sheep and Human Breast Milk: A Source of Neonatal Exposure. *Biolog Trace Element Res.*, 56:143-52, 1997.
- ²⁰ Hahn, LJ; et al. Whole-Body Imaging of the Distribution of Mercury Released from Dental Fillings into Monkey Tissues. *FASEB J.* 4:3256-609 1990.
- ²¹ Danscher, G; et al. Traces of Mercury in Organs from Primates with Amalgam Fillings *Experim Molec Pathol*, 52:291-9, 1990.
- ²² Drasch, G; et al. Mercury Burden of Human Fetal and Infant Tissues. *Europ J Pediatrics*, 153(8):607-10, 1994.
- ²³ Eggleston, DW; Nylander, M. Correlation of Dental Amalgam with Mercury in Brain Tissue. *J Prosth Dent*, 58(6):704-7, 1987.
- ²⁴ Friberg, L; et al. Mercury in the Central Nervous System in Relation to Amalgam Fillings. *Swed Med J*, 83(7):519-22, 1986.
- ²⁵ Nylander, M. Mercury in Pituitary Glands of Dentists. *Lancet*:442.1, 22 Feb 1986.
- ²⁶ Nylander, M; et al. Mercury concentrations in the human brain and kidneys in relation to exposure from dental amalgam fillings. *Swed Dent J*, 11:179-87, 1987
- ²⁷ Abraham, JE; Svare, CW; Frank, CW. The effect of dental amalgam restorations on blood mercury levels. *J Dent Res.* 63: 71-73 (1984).
- ²⁸ Snapp, KR; Boyer, DB; Peterson, LC; Svare, CW. The contribution of dental amalgam to mercury in blood. *J Dent Res.* 68: 780-785 (1989).
- ²⁹ Molin, M; Bergman, B; Marklund, SL; Schutz, A; Skerfving, S. Mercury, selenium, and glutathione peroxidase before and after amalgam removal in man. *Acta Odontol Scand*, 48: 189-202 (1990).
- ³⁰ Malmstrom, C; et al. Amalgam-derived Mercury in Feces. Conference on Trace Elements in Health and Disease, Stockholm, 15-29 May, 1992.
- ³¹ Skare, I; Enkvist, A. op. cit.
- ³² Skerfving, S. Exposure to mercury in the population. In: *Advances in Mercury Toxicology*, Suzuki, et. al., eds, New York, Plenum Press (1991)
- ³³ Snapp, et. al, op. cit.
- ³⁴ Molin, et. al, op. cit.
- ³⁵ Aposhian, HV; et al. Urinary mercury after administration of 2,3-dimercaptopropane-1-sulfonic acid: Correlation with dental amalgam score. *FASEB J*, 6:2472-6, 1992.
- ³⁶ Zander, D; et al. Studies on Human Exposure to Mercury. III: DMPS Induced Mobilization of Mercury in Subjects With and Without Amalgam Fillings. *Zentrablatt Fur Hygiene und Umweltmedizin*, 192:5, Feb 1992.
- ³⁷ Hermann, M; Schweinsberg, F. [Biomonitoring and evaluation of mercury burden from amalgam fillings: mercury analysis in urine before and after oral lavage with DMPS, and in hair] *Zbl Hyg* 194: 271-291 (1993). (German with English summary)
- ³⁸ Goldman LR, Shannon MW; Technical report: mercury in the environment: implications for pediatricians. American Academy of Pediatrics: Committee on Environmental Health. *Pediatrics*. 108:197-205. (2001)
- ³⁹ Berlin, M; et al. Prenatal Exposure to Mercury Vapor: Effects on Brain Development. *The Toxicologist*, 12(1):7(A245), (1992).
- ⁴⁰ Grandjean, P; et al. Cognitive Deficit in 7 Year Old Children With Prenatal Exposure to Methyl Mercury. *Neurotoxicol Teratol.*, 19(6):417-28, (1997).
- ⁴¹ Grandjean, P; et al. Cognitive Performance of Children Prenatally Exposed to "Safe" Levels of Methyl Mercury. *Environ Research*, 77(2):165-72, May (1998).
- ⁴² Danielsson, BR; et al. Behavioral Effects of Prenatal Metallic Mercury Inhalation Exposure in Rats. *Neurotoxicol Teratol.*, 15(6):391-6, (1993).
- ⁴³ Aschner, M; et al. Metallothionein Induction in Fetal Rat Brain and Neonatal Primary Astrocyte Cultures by In Utero Exposure to Elemental Mercury Vapor. *Brain Res.*, 778(1):222-32, (1997).
- ⁴⁴ Eccles, CU; Annau, Z. Prenatal Methyl Mercury Exposure: II. Alterations in Learning and Psychotropic Drug Sensitivity in Adult Offspring. *Neurobehav Toxicol Teratol.*, 4(3):377-82, May (1982).
- ⁴⁵ Fredriksson, A; et al. Behavioral Effects of Neonatal Metallic Mercury Exposure in Rats. *Toxicology*, 74(2-3):151-60, Sep (1992).
- ⁴⁶ <http://altcorp.com/thimerosal.htm>
- ⁴⁷ Vimy, MJ; Takahashi, Y; Lorscheider, FL.. Maternal-fetal distribution of mercury ²⁰³Hg released from dental amalgam fillings. *Amer J Physiol*, 258(RICP 27):R939-45, (1990).
- ⁴⁸ Vimy, MJ; Hooper, DE; King, WW; Lorscheider, FL.. Mercury from Maternal "Silver Fillings in Sheep and Human Breast Milk: A Source of Neonatal Exposure. *Biolog Trace Element Res.*, 56:143-52, (1997).

-
- ⁴⁹ Clarkson, TW; Hursh, JB; Sager, PR; Syverson, TLM. Mercury. In *Biological Monitoring of Toxic Metals*. Clarkson, et. al., eds. pp. 199-246, Plenum Press, New York (1988)
- ⁵⁰ Drasch, G, et. al., (1994) op. cit.
- ⁵¹ Drasch, G; et al. Mercury in Human Colostrum and Early Breast Milk. Its Dependence on Dental Amalgam and Other Factors. *J Trace Elem Med Biol.*, 12(1):23-7, Mar (1998).
- ⁵² Vimy, MJ, et. al. (1997) op. cit.
- ⁵³ Richardson, GM; Allan, M. A Monte Carlo assessment of mercury exposure and risks from dental amalgam. *Human and Ecol Risk Assess.* 2: 709-761 (1996).
- ⁵⁴ Richardson, GM. Assessment of mercury exposure and risks from dental amalgam: Final Report, Medical Devices Bureau, Health Canada, Ottawa.
- ⁵⁵ "The Safety of Dental Amalgam." Health Canada, Dept. of Supply and Services Canada Cat. H49-105/1996E ISBN 0-662-81449-5 (1996)
- ⁵⁶ North American Contact Dermatitis Group. Epidemiology of contact Dermatitis in North America: 1972. *Arch Dermatol*, 108:537-40, (1973)
- ⁵⁷ Clifford, WJ. Personal communication
- ⁵⁸ Djerassi, E; Berova, N. The possibilities of allergic reactions from silver amalgam restorations. *Internat Dent J*, 19(4):481-8, 1969.
- ⁵⁹ Finne, K; et al. Oral Lichen Planus and Contact Allergy to Mercury. *Int J Oral Surg.*, 11:236-9, 1982.
- ⁶⁰ Miller, EG, et. al. Prevalence of mercury hypersensitivity in dental students. *J Dent Res.* 64: Special Issue, p. 338, Abstract #1472, (1985).
- ⁶¹ Druet, P; et al. Immune dysregulation and auto-immunity induced by toxic agents. *Transplant Proc*, 14(3):482-4, (1982).
- ⁶² Druet, P; Bernard, A; Hirsch, F; Weening, JJ; Gengoux, P; Mahieu, P; Berkeland, S. Immunologically Mediated Glomerulonephritis Induced by Heavy Metals. *Arch. Toxicol*, 50:187-94, (1982).
- ⁶³ Hirsch, F; Kuhn, J; Ventura, M; Vial, MC; Fournie, G; Druet, P. Autoimmunity Induced by HgCl₂ in Brown-Norway Rats: I. Production of monoclonal antibodies. *J Immunol*, 136(9):3272-6, (1986).
- ⁶⁴ Hultman, P; Johansson, U; Turley, SJ; Lindh, U; Enestrom, S; Pollard, KM. Adverse Immunological Effects and Autoimmunity Induced by Dental Amalgam and alloy in Mice. *FASEB J*, 8(14):1183-90, (1994).
- ⁶⁵ Casarett and Doull's. *Toxicology: The Basic Science of Poisons*, 3rd Ed., Macmillan Pub Co., NY, 1986.
- ⁶⁶ Boyd ND; Benediktsson, M; Vimy, MJ; Hooper, DE; Lorscheider, FL. Mercury from dental "silver" tooth fillings impairs sheep kidney function. *Amer J Physiol*, 261(RICP 30):R1010-4, (1991).
- ⁶⁷ Molin, M; et. al. (1990) op. cit.
- ⁶⁸ Gilbert, MP; Summers, AO. The distribution and divergence of DNA sequences related to the Tn21 and Tn501 mer-operons. *Plasmid* 20: 127-136 (1988).
- ⁶⁹ Summers, AO; Wireman, J; Vimy, MJ; Lorscheider, FL; Marshall, B; Levy, SB; Bennet, S; Billard, L. Mercury released from dental "silver" fillings provokes an increase in mercury- and antibiotic- resistant bacteria in oral and intestinal flora of primates. *Antimicrob Agents and Chemother.* 37: 825-834 (1993).
- ⁷⁰ Echeverria, D; Heyer, N; Martin, MD; Naleway, CA; Woods, JS; Bittner, AC. Behavioral Effects of Low-Level Exposure to Hg⁰ Among Dentists. *Neurotoxicol Teratol*, 17(2):161-8, (1995).
- ⁷¹ Gonzalez-Ramirez, D; Maiorino, RM; Zuniga-Charles, M; Xu, z; Hurlbut, KM; Junco-Munoz, P; Aposhian, MM; Dart, RC; Gama, JHD; Escheverria, D; Woods, JS; Aposhian, HV. . Sodium 2,3-Dimercaptopropane-1-Sulfonate Challenge Test for Mercury in Humans: II. Urinary Mercury, Porphyrins and Neurobehavioral Changes of Dental Workers in Monterrey, Mexico. *J Pharmacol Experim Ther*, 272:264-74, (1995).
- ⁷² Echeverria, D; et al. Neurobehavioral Effects From Exposure to Amalgam Hg⁰: New Distinctions Between Recent Exposure and Hg Body Burden. *FASEB J.*, 12:971-80, (1998).
- ⁷³ Naleway, C; Sakaguchi, R; Mitchell, E; Muller, T; Ayer, WA; Hefferren, JJ. Urinary mercury levels in US dentists, 1975-1983: review of Health Assessment Program. *J Am Dent Assoc* 111: 37-42, (1985).
- ⁷⁴ Rowland, AS; et al. The Effect of Occupational Exposure to Mercury Vapour on the Fertility of Female Dental Assistants. *Occupat Environ Med.*, 51:28-34, 1994.
- ⁷⁵ Gordon, H. Pregnancy in Female Dentists: A Mercury Hazard. In: *Proceedings of International Conference on Mercury Hazards in Dental Practice*. Glasgow, Scotland, 2-4 Sep 1981.
- ⁷⁶ Gerhard, I; et al. Heavy Metals and Fertility. *J Toxicol Environ Health*, 54(8):593-611, Aug 1998.
- ⁷⁷ Lee, IP. Effects of Environmental Metals on Male Reproduction. In: *Reproduction and Developmental Toxicity of Metals*; Ed: Clarkson, TW; et al.:253-78, Plenum Press, NY, 1983.
- ⁷⁸ Panova, Z; Dimitrov, G. Ovarian Function in Women Having Professional Contact With Metallic Mercury. *Akusherstvoi Ginekologiya*, 13(1):29-34, 1974.

-
- ⁷⁹ Uzzell, GP; Oler, J. Chronic low level mercury exposure and neuropsychological functioning. *J Clin Exper Neuropsych.* 8: 581-593 (1986)
- ⁸⁰ Ehmann WD, Markesbery WR, Alauddin M, Hossain TI, Brubaker EH. Brain trace elements in Alzheimer's disease. *Neurotoxicology Spring*; 7(1):195-206 (1986)
- ⁸¹ Thompson CM, Markesbery WR, Ehmann WD, Mao YX, Vance DE. Regional brain trace-element studies in Alzheimer's disease. *Neurotoxicology Spring*; 9(1):1-7 (1988)
- ⁸² Wenstrup D, Ehmann WD, Markesbery WR. Trace element imbalances in isolated subcellular fractions of Alzheimer's disease brains. *Brain Res Nov* 12;533(1):125-31 (1990)
- ⁸³ Cornett CR, Markesbery WR, Ehmann WD Imbalances of trace elements related to oxidative damage in Alzheimer's disease brain. *Neurotoxicology Jun*; 19(3):339-45 (1998)
- ⁸⁴ Basun H, Forssell LG, Wetterberg L, Winblad B. Metals and trace elements in plasma and cerebrospinal fluid in normal aging and Alzheimer's disease. *J Neural Transm, Park Dis Dement Sect.* 3(4):23
- ⁸⁵ Hock C, Drasch G, Golombowski S, Muller-Spahn F, Willershausen-Zonnchen B, Schwarz P, Hock U, Growdon JH, Nitsch RM. Increased Blood Mercury Levels in Patients With Alzheimer's Disease. *J Neural Transm.*, 105(1):59-68, (1998).
- ⁸⁶ Saxe SR, Wekstein MW, Kryscio RJ, Henry RG, Cornett CR, Snowdon DA, Grant FT, Schmitt FA, Donegan SJ, Wekstein DR, Ehmann WD, and Markesbery WR. Alzheimer's disease, dental amalgam and mercury. *JADA February* 130: 191-199 (1999).
- ⁸⁷ Haley, B. Khatoon, S; et al. GTP binding to the b-subunit of tubulin is greatly reduced in Alzheimers Disease. ASBC 1987.
- ⁸⁸ Duhr, EF; et al. HgEDTA complex inhibits GTP interactions with the E site of Brain B-Tubulin. *Toxicol Appl Pharmacol*, 122:273-80, 1993.
- ⁸⁹ Haley, B. Pendergrass, J; et al. Use of photoaffinity labeling and 2-D electrophoresis to identify changes in nucleotide binding proteins in brain and CSF: A Potential diagnostic technique for neurological diseases. *Amer Assoc Pharmaceut Scientists*, 1995.
- ⁹⁰ Haley, B. Pendergrass, JC; et al. Meso-2,3-dimercaptosuccinic acid (DMSA) partially restores [32P]8N3GTP-b-tubulin interactions to both Alzheimer's Diseased (AD) brains and to HgEDTA treated control brains. *Experim Biol*, 1993.
- ⁹¹ Olivieri, G., Brack, Ch., Muller-Spahn, F., Stahelin, H.B., Herrmann, M., Renard, P; Brockhaus, M. and Hock, C. Mercury Induces Cell Cytotoxicity and Oxidative Stress and Increases b-amyloid Secretion and Tau Phosphorylation in SHSY5Y Neuroblastoma Cells. *J. Neurochemistry* 74, 231-231, 2000.
- ⁹² Haley, B. Duhr, E; et al. Hg²⁺ induces GTP-tubulin interactions in rat brain similar to those observed in Alzheimer's Disease. *FASEB A493*, 1991.
- ⁹³ Lorscheider, FL; et al. Mercury Vapor Exposure Inhibits Tubulin Binding to GTP in Rat Brain: A Molecular Lesion also Present in Human Alzheimer Brain. *FASEB J*, 9(4):3845, 1995.
- ⁹⁴ Pendergrass, JC; Haley, BE; Vimy, MJ; Winfield, SA; Lorscheider, FL. Mercury Vapor Inhalation Inhibits Binding of GTP to Tubulin in Rat Brain: Similarity to a Molecular Lesion in Alzheimer Diseased Brain. *Neurotoxicology*, 18(2):315-324, 1997.
- ⁹⁵ www.altcorp.com/amalgampage/htm
- ⁹⁶ Leong, CCW; Naweed, IS; Lorscheider, FL. Retrograde degeneration of neurite membrane structural integrity of nerve growth cones following in vitro exposure to mercury. *Neuroreport* 12: 733-737 (2000).
- ⁹⁷ Bioprobe Newsletter, March, 1993.